



Observational Study

Intraprocedural gastric juice analysis as compared to rapid urease test for real-time detection of *Helicobacter pylori*

Riccardo Vasapolli, Florent Ailloud, Sebastian Suerbaum, Jens Neumann, Nadine Koch, Lukas Macke, Jörg Schirra, Julia Mayerle, Peter Malfertheiner, Christian Schulz

Specialty type: Gastroenterology and hepatology

Provenance and peer review:

Unsolicited article; Externally peer reviewed.

Peer-review model: Single blind

Peer-review report's scientific quality classification

Grade A (Excellent): 0
Grade B (Very good): B, B
Grade C (Good): 0
Grade D (Fair): 0
Grade E (Poor): 0

P-Reviewer: Noh CK, South Korea; Rocha R, Brazil

Received: November 19, 2022

Peer-review started: November 19, 2022

First decision: December 10, 2022

Revised: January 15, 2023

Accepted: February 22, 2023

Article in press: February 22, 2023

Published online: March 14, 2023



Riccardo Vasapolli, Nadine Koch, Lukas Macke, Jörg Schirra, Julia Mayerle, Peter Malfertheiner, Christian Schulz, Medical Department II, University Hospital LMU Munich, Munich 81377, Germany

Riccardo Vasapolli, Sebastian Suerbaum, Lukas Macke, Christian Schulz, Deutsches Zentrum für Infektionsforschung, Partner Site Munich, Munich 81377, Germany

Florent Ailloud, Sebastian Suerbaum, Max von Pettenkofer Institute, Faculty of Medicine, Ludwig-Maximilians University of Munich, Munich 80336, Germany

Florent Ailloud, Sebastian Suerbaum, National Reference Center for *Helicobacter pylori*, Munich 81377, Germany

Jens Neumann, Institute of Pathology, Faculty of Medicine, Ludwig-Maximilians-University of Munich, Munich 81377, Germany

Corresponding author: Christian Schulz, MD, Deputy Director, Medical Department II, University Hospital LMU Munich, Marchionini Strasse 15, Munich 81377, Germany.
chr.schulz@med.uni-muenchen.de

Abstract

BACKGROUND

Endofaster is an innovative technology that can be combined with upper gastrointestinal endoscopy (UGE) to perform gastric juice analysis and real-time detection of *Helicobacter pylori* (*H. pylori*).

AIM

To assess the diagnostic performance of this technology and its impact on the management of *H. pylori* in the real-life clinical setting.

METHODS

Patients undergoing routine UGE were prospectively recruited. Biopsies were taken to assess gastric histology according to the updated Sydney system and for rapid urease test (RUT). Gastric juice sampling and analysis was performed using the Endofaster, and the diagnosis of *H. pylori* was based on real-time ammonium measurements. Histological detection of *H. pylori* served as the diagnostic gold standard for comparing Endofaster-based *H. pylori* diagnosis with RUT-based *H.*

pylori detection.

RESULTS

A total of 198 patients were prospectively enrolled in an *H. pylori* diagnostic study by Endofaster-based gastric juice analysis (EGJA) during the UGE. Biopsies for RUT and histological assessment were performed on 161 patients (82 men and 79 women, mean age 54.8 ± 19.2 years). *H. pylori* infection was detected by histology in 47 (29.2%) patients. Overall, the sensitivity, specificity, accuracy, positive predictive value, and negative predictive value (NPV) for *H. pylori* diagnosis by EGJA were 91.5%, 93.0%, 92.6%, 84.3%, and 96.4%, respectively. In patients on treatment with proton pump inhibitors, diagnostic sensitivity was reduced by 27.3%, while specificity and NPV were unaffected. EGJA and RUT were comparable in diagnostic performance and highly concordant in *H. pylori* detection (κ -value = 0.85).

CONCLUSION

Endofaster allows for rapid and highly accurate detection of *H. pylori* during gastroscopy. This may guide taking additional biopsies for antibiotic susceptibility testing during the same procedure and then selecting an individually tailored eradication regimen.

Key Words: *Helicobacter pylori* diagnostic; Chronic gastritis; Gastric juice; Endofaster; Rapid urease test; Antimicrobial susceptibility testing

©The Author(s) 2023. Published by Baishideng Publishing Group Inc. All rights reserved.

Core Tip: Diagnosis of *Helicobacter pylori* (*H. pylori*) infection can be rapidly achieved within the framework of gastroscopy by rapid urease test (RUT) or by gastric juice analysis with Endofaster. In this prospective observational study, we compared the accuracy of these two methods. Gastric juice analysis with Endofaster could reliably detect *H. pylori* with high accuracy, showing a diagnostic performance comparable to that of RUT and a major advantage of an immediate result. Intraprocedural *H. pylori* detection (or exclusion) is crucial to optimize the diagnostic approach and improve the management of infection. The diagnosis of Endofaster may guide additional sampling for antibiotic susceptibility testing in positive patients or avoid unnecessary biopsies in negative patients.

Citation: Vasapolli R, Ailloud F, Suerbaum S, Neumann J, Koch N, Macke L, Schirra J, Mayerle J, Malfertheiner P, Schulz C. Intraprocedural gastric juice analysis as compared to rapid urease test for real-time detection of *Helicobacter pylori*. *World J Gastroenterol* 2023; 29(10): 1494-1503

URL: <https://www.wjgnet.com/1007-9327/full/v29/i10/1494.htm>

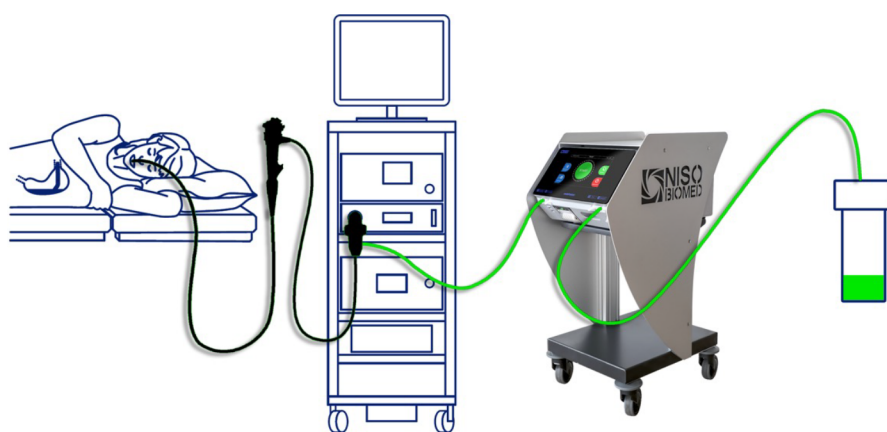
DOI: <https://dx.doi.org/10.3748/wjg.v29.i10.1494>

INTRODUCTION

Helicobacter pylori (*H. pylori*) infects nearly half of the world's population, with variable prevalence rates ranging from 20%-30% in Western countries to > 70% in Africa[1]. *H. pylori* infection causes chronic active gastritis and may lead to severe complications including gastroduodenal ulcers, gastric cancer and mucosa-associated lymphoid tissue lymphoma[2]. The diagnosis of active *H. pylori* infection is achieved by non-invasive tests such as the urea breath test (UBT) and stool antigen tests (SAT), as well as invasive methods based on endoscopy and gastric biopsies for histological assessment, rapid urease test (RUT), culture and molecular tests.

Current guidelines recommend testing for *H. pylori* in all patients undergoing upper gastrointestinal endoscopy (UGE)[3]. The Endofaster has been introduced as new diagnostic device, which consents the detection of *H. pylori* by performing biochemical analysis of gastric juice aspirated during gastroscopy. Previous validation studies have shown that this device has high accuracy for *H. pylori* detection and reported diagnostic values similar to those of UBT and histology[4,5]. The diagnostic performance of the Endofaster has not been compared with that of the RUT, which shares a similar characteristic in terms of providing results in a short-term temporal context through endoscopic examination. This allows for therapeutic management immediately after the diagnostic procedure.

The aim of this prospective study was to validate the diagnostic performance of the Endofaster for *H. pylori* detection in patients who underwent UGE compared to conventional RUT.



DOI: 10.3748/wjg.v29.i10.1494 Copyright ©The Author(s) 2023.

Figure 1 Schematic diagram of Endofaster device's montage.

MATERIALS AND METHODS

Study population

Consecutive patients undergoing routine UGE to investigate dyspepsia or other alarming symptoms (weight loss, anemia, vomiting, abdominal pain, or dysphagia) were prospectively recruited at the Ludwig Maximilians University Hospital in Munich from January to June 2022.

Subjects were recruited within the ERANET Bavaria and Helicopredict projects (German clinical trials register, DRKS-ID: DRKS00028629), large-scale prospective studies focused on studying different aspects of *H. pylori* infection, including improving the diagnosis and management of *H. pylori*, determining local antibiotic resistance spectrum, with the aim of developing a genotypic resistance testing database for predicting antibiotic susceptibility and evaluating the impact of the microbiome of the upper gastrointestinal tract on gastric carcinogenesis.

The study was approved by the local ethics committee and government authorities and was conducted in accordance with current Good Clinical Practice guidelines and the Declaration of Helsinki [6]. All recruited subjects provided written informed consent for participation. Previous gastric surgery and intake of anticoagulants or any antibiotic therapy within 4 wk prior to endoscopy were exclusion criteria. Regular use of proton pump inhibitors (PPI) or previous *H. pylori* eradication therapy did not represent exclusion criteria, but were recorded in detail. Only patients not taking a PPI or *H. pylori* treatment-naïve patients were considered to meet the desired minimum sample size.

Endoscopic procedure and histological assessment

Enrolled patients underwent a diagnostic UGE using standard video gastroscopes (GIF-HQ190, Olympus, Tokyo, Japan). All examinations were performed with sedation using Propofol and/or Midazolam. An analysis of gastric juice was performed at the beginning of the UGE by Endofaster. Special attention was paid during intubation: The stomach was handled first and no fluid was allowed to be sucked during passage through the oral cavity or esophagus. In order to avoid possible dilution of gastric juice prior to collection the administration of endoscopic premedications (*i.e.* dimethicone, N-acetylcysteine, pronase *etc.*) before endoscopy were not allowed. Furthermore, washing with water and cleaning the endoscopic lens were avoided until sampling was completed. After endoscopic assessment of the mucosa, gastric biopsies were obtained. Two biopsies - one from antrum and one from corpus (both from the greater curvature) - were taken for the RUT (Pronto Dry® New, Medical Instruments Corporation, Herford, Germany). RUT was performed according to the manufacturer's instructions and assessed for positive response during gastroscopy and 1 h after biopsy sampling. The inspection time taken to perform the diagnostic UGE (excluding the time spent on gastric juice aspiration and on biopsy sampling) and the time it took until first detection of *H. pylori* positivity by RUT were recorded. Further biopsies (2 from antrum, 1 from angulus and 2 from corpus) were subjected to routine histology according to the updated Sydney system[7] and current guidelines[3]. In each biopsy sampling set the following stainings were performed: Hematoxylin and eosin, periodic acid-Schiff and a *H. pylori* specific staining (modified Giemsa staining).

Endofaster analysis

Real-time gastric juice analysis was performed using an Endofaster 21-42 (NISO Biomed, Turin, Italy), which is interposed between the endoscope and the suction system (Figure 1). This innovative device analyzes the first 3.3 mL of gastric juice aspirated at the beginning of the UGE. The Endofaster provides information regarding gastric pH based on hydrogen ion concentration and *H. pylori* detection based on

the measurement of ammonium derived from bacterial urease activity within 60-90 s[4,5]. Considering that approximately 10-20 s (max 30 s) are needed to aspirate the gastric juice through the scope a final *H. pylori* diagnosis is provided within the first 2 min from the beginning of the endoscopic procedure. Except for the time spent on the initial gastric juice collection no additional time is required for Endofaster use during the endoscopic procedure. In line with previous studies, we used a cut-off value of > 62 ppm/mL to indicate the presence of *H. pylori*[8].

Statistical analyses

Descriptive statistical analysis was performed using IBM SPSS Statistics 23.0.0 (IBM Corporation, New York, NY, United States). Numerical variables were expressed as mean \pm SD. Sensitivity, specificity, accuracy, positive predictive value (PPV), and negative predictive value (NPV) were calculated for both Endofaster and RUT using histology as the gold standard. The concordance between Endofaster and RUT results was assessed by using Cohen's κ -value. The McNemar test was used to compare sensitivities and specificities between the two tests.

Sample size estimation was based on a 95%CI and the calculation methods of Buderer *et al*[9] were applied using following formula:

$$n_{se} = \frac{Z_{\frac{\alpha}{2}}^2 \hat{Se} (1 - \hat{Se})}{d^2 \times Prev}$$

$$n_{sp} = \frac{Z_{\frac{\alpha}{2}}^2 \hat{Sp} (1 - \hat{Sp})}{d^2 \times (1 - Prev)}$$

Where Z is the normal distribution value set to 1.96, corresponding to the 95%CI, and d is the maximum acceptable width of the 95%CI, set at 10%. Based on a previous study, Endofaster had a sensitivity (Se) of 97.1% and a specificity (Sp) of 89.7% for *H. pylori* detection[5]. Recently, the prevalence of *H. pylori* infection ($Prev$) in Germany was estimated to be 35.3% (95%CI: 31.2-39.4)[1]. As a result, using the criteria listed above, this study required a minimum of 31 *H. pylori*-positive patients (n_{se}) and 55 *H. pylori*-negative patients (n_{sp}), resulting in a minimum total sample size of 86 subjects. Patients with PPI use or prior *H. pylori* eradication therapy were not considered to achieve the minimum sample size required. All authors had access to the study data and reviewed and approved the final manuscript.

RESULTS

Characteristics of the study cohort

A total of 198 patients undergoing elective UGE were enrolled. Of these, 182 underwent gastric juice analysis with the Endofaster. After excluding patients who reported antibiotic intake within the last 4 wk ($n = 10$, 5.2%), patients who could not undergo biopsy due to anticoagulation therapy ($n = 8$, 4.1%) and patients with insufficient volume of aspirated gastric juice for Endofaster analysis ($n = 13$, 6.7%) a total of 161 patients (male: 82, female: 79, mean age 54.8 ± 19.2 years) were included in the analysis. 67 (41.6%) patients were on ongoing PPI therapy and 94 patients (58.4%) did not report any PPI therapy. The demographic, endoscopic, and histopathological characteristics of the study cohort are shown in Table 1. A flow chart of the study's recruitment is shown in Figure 2.

Diagnostic performance of Endofaster and RUT for *H. pylori* detection

The average duration of the diagnostic UGE was 8.5 min. *H. pylori* infection was diagnosed in 47 (29.2%) patients on histopathology. Endofaster results were positive in 51 patients (31.6%), while RUT was positive in 45 (28.0%) cases. A positive RUT reaction was detected during endoscopy in 37 subjects (78.7%), with a mean positive reaction time of 16.4 min. The overall diagnostic performances of Endofaster and RUT for *H. pylori* detection as compared to histology (gold standard) are shown in Table 2. Sensitivity, specificity, accuracy, PPV and NPV were 91.5%, 93.0%, 92.6%, 84.3% and 96.4% for Endofaster, and 93.6%, 99.1%, 97.5%, 97.8% and 97.4% for RUT, respectively. No significant differences were observed in the diagnostic performances of the Endofaster and the RUT ($P > 0.05$). This was confirmed by an almost perfect agreement of *H. pylori* detection between the two tests (κ -value = 0.85).

Both Endofaster and RUT showed excellent diagnostic performances when considering only patients without ongoing PPI therapy ($n = 94$). In this subgroup, 37 (39.4%) subjects were histopathologically diagnosed as positive for *H. pylori*.

Among patients treated with PPI ($n = 67$), the presence of *H. pylori* was detected by histology in 10 subjects (14.9%). In this subgroup, a reduction in sensitivity, PPV and accuracy was observed for both Endofaster and RUT, whereas specificity and NPV remained almost unchanged (Table 2). Again, in the subgroup analysis, there were no significant differences in diagnostic performances between Endofaster and RUT ($P > 0.05$).

Table 1 Demographic, endoscopic and histopathological characteristics of the patients included in the study, *n* (%)

Characteristics	Value
Overall	161
Male	82 (50.9)
Female	79 (49.1)
Age, mean \pm SD (range) yr	54.8 \pm 19.2 (19-90)
<i>H. pylori</i> positive	47 (29.2)
<i>H. pylori</i> negative	114 (70.8)
Patients without PPI therapy	94 (58.4)
Male	46 (48.9)
Female	48 (51.1)
Age, mean \pm SD (range) yr	50.3 \pm 19.2 (19-86)
<i>H. pylori</i> positive	37 (39.4)
<i>H. pylori</i> negative	57 (60.6)
Patients with PPI therapy	67 (41.6)
Male	36 (53.7)
Female	31 (46.3)
Age, mean \pm SD (range) yr	58.9 \pm 19.2 (23-90)
<i>H. pylori</i> positive	10 (14.9)
<i>H. pylori</i> negative	57 (85.1)
Endoscopic and histopathological findings ¹	
Normal	13 (8.1)
Gastroesophageal reflux disease	26 (16.1)
Chronic gastritis	84 (52.2)
Erosive gastritis	32 (19.9)
Gastric ulcer	5 (3.1)
Duodenal ulcer	3 (1.9)
Gastritis with low-grade PL	36 (22.4)
Gastritis with high-grade PL	4 (2.5)
Others ²	6 (3.7)

¹Different conditions may coexist. Precancerous lesions include gastric atrophy and/or intestinal metaplasia, assessed according to the Operative Link on Gastritis Assessment (OLGA) and Operative Link on Gastric Intestinal Metaplasia systems (low grade if OLGA/IM < 3, high grade if OLGA/IM \geq 3)[23, 24].

²"Others" include patients with gastric cancer (*n* = 1), gastric lymphoma (*n* = 1), Barrett's esophagus (*n* = 2), gastric hyperplastic polyps (*n* = 1) and gastric neuroendocrine tumors (*n* = 1).

H. pylori: *Helicobacter pylori*; PPI: Proton pump inhibitors.

DISCUSSION

Several diagnostic methods are performed on biopsies obtained during the UGE to detect *H. pylori* with high accuracy. They are highly accurate, but have the limitation to delay even a few days in providing diagnostic results, thus not allowing an immediate therapeutic decision. RUT is the only exception in clinical practice that allows relatively rapid detection of *H. pylori*, usually within 1 h after UGE[10-12].

Here, we report on the diagnostic performance of Endofaster-based gastric juice analysis (EGJA), an innovative technology that allows intraprocedural *H. pylori* detection compared to RUT. We found that the high accuracy (> 90%) of EGJA was comparable to that of RUT for *H. pylori* detection, confirming previous reports of the high accuracy of EGJA compared to histology[4,5,8,13]. A previous prospective study of EGJA in 182 patients determined the sensitivity, specificity and accuracy of *H. pylori* to be 97.1%, 89.7% and 92.6%, respectively, compared to histology being used as the gold standard as well as

Table 2 Diagnostic performance of the Endofaster® and rapid urease test (ProntoDry®) for the diagnosis of *Helicobacter pylori* infection in the study cohort, % (95%CI)

	Endofaster			Rapid urease test		
	Overall	No PPI	Ongoing PPI therapy	Overall	No PPI	Ongoing PPI therapy
Sensitivity	91.5 (79.6-97.6)	97.3 (85.8-99.9)	70.0 (34.8-93.3)	93.6 (82.5-98.7)	97.3 (85.8-99.9)	80.0 (44.4-97.5)
Specificity	93.0 (84.6-96.9)	96.5 (87.9-99.6)	89.5 (78.5-96.0)	99.1 (95.2-100)	100 (93.7-100)	98.3 (90.6-100)
PPV	84.3 (73.3-91.3)	94.7 (82.2-98.6)	53.9 (33.1-73.4)	97.8 (86.2-99.7)	100 (-)	88.9 (52.8-98.3)
NPV	96.4 (91.2-98.6)	98.2 (88.8-99.7)	94.4 (86.8-97.8)	97.4 (92.7-99.1)	98.3 (89.2-99.8)	96.6 (89.0-99.0)
Accuracy	92.6 (87.3-96.1)	96.8 (91.0-99.3)	86.6 (76.0-93.7)	97.5 (93.8-99.3)	98.9 (94.2-100)	95.5 (87.5-99.1)

Overall ($n = 161$), in patients with ongoing proton pump inhibitors (PPI) therapy ($n = 67$) and in patients without PPI therapy ($n = 94$). Values are shown as percentages with 95%CI. PPI: Proton pump inhibitor; PPV: Positive predictive value; NPV: Negative predictive value.

UBT, which was used for reclassification of *H. pylori* status in case of discordance between EGJA and histology results[5]. A multicenter study of 525 consecutive patients reported an overall sensitivity, specificity and accuracy of 87%, 84% and 85%, respectively, when compared to histology[8].

We have observed impaired diagnostic sensitivity in patients with PPI in EGJA and RUT, which is a common phenomenon for all tests, including non-invasive tests[3,14]. In the context of PPI intake, only histology remains highly sensitive when gastric biopsies are taken from the proximal stomach[15,16]. This is related to the PPI-induced shift from antrum-predominant to corpus-predominant gastritis. We found that 3 out of 4 false negatives and 6 out of 8 false positives (75%) in EGJA were registered in patients on PPI therapy. Two of the three false negatives (66%) diagnosed by the RUT were PPI users. EGJA and RUT rely on the same principles related to ammonium concentration and *H. pylori* urease activity. Therefore, both tests are influenced by the reduction of bacterial load by PPI, which may lead to false negative results. Furthermore, an elevated pH in the stomach environment may lead to an overgrowth of other non-*H. pylori* bacteria with urease activity[17]. Several different urease-positive bacterial strains, such as *Staphylococcus capitis subsp. urealyticus* and *Streptococcus salivarius*, have been isolated in gastric juice and mucosal samples from patients with gastric hypochloridria[18]. The higher abundance of these strains may interfere with urea metabolism and explain the increased number of false-positive cases among patients on PPI therapy. It is necessary to analyze the gastric microbiota and functionality profiles of PPI patients in order to further address this interesting topic. In our study, the low prevalence of *H. pylori*-infected subjects (only 14.9%) within the group of patients on PPI therapy is a limitation because of an underpowered statistical analysis. Using histology as the gold standard for *H. pylori*-diagnosis in a cohort with relatively low-prevalence of *H. pylori* may represent a further limitation of this study. Histopathological diagnosis of *H. pylori* may suffer from potential sampling error due to the patchy distribution of the bacterium[19]. However, by using the updated Sydney system based on biopsies from 5 different sites and applying different staining methods for *H. pylori* detection the accuracy of *H. pylori*-diagnosis by histology is not inferior to any non-invasive test (13C-UBT/SAT). In support for the validity of histology as gold standard for *H. pylori* detection, we found also no indirect signs of *H. pylori*-gastritis (*i.e.* neutrophils infiltration in the gastric mucosa) in the absence of *H. pylori*.

EGJA has the advantage of obtaining more rapid diagnostic results when performing endoscopy compared to RUT. During endoscopy (within a time period of approximately 10 min), a positive signal in the RUT for the presence of *H. pylori* was recorded in 78.7% of those producing *H. pylori* positivity at the end of the reading time in our study, consistent with the time interval of response reported in previous validation studies[12,20], whereas EGJA resulted in the diagnosis of *H. pylori* within 2 min after starting with UGE. The intraprocedural detection of *H. pylori* infection combined with measurement of gastric pH can guide the endoscopist on the most appropriate approach to complete the diagnostic assessment, *i.e.*, whether or not to carry out additional biopsies for gastritis severity staging and antibiotic susceptibility testing (AST). This has become an absolute requirement for the selection of the eradication regimen due to the high antibiotic resistance rates of clarithromycin, metronidazole and fluoroquinolones[21]. Real-time detection of *H. pylori* suggests carrying out additional biopsies for AST during UGE and selecting an *H. pylori* eradication regimen accordingly.

Such a strategy would have a substantial impact on cost-effectiveness by reducing the duration of the procedure and lowering costs due to histological or microbiological analysis of negative gastric biopsies, an aspect that has been previously addressed by others[8].

Future studies will explore the possibility of combining EGJA with *in situ* molecular genetic antibiotic resistance testing. Promising data in this field were revealed by a recent meta-analysis of four studies that evaluated gastric juice-based genotypic detection of *H. pylori* antibiotic resistance to clarithromycin compared to standard culture-based methods[22].

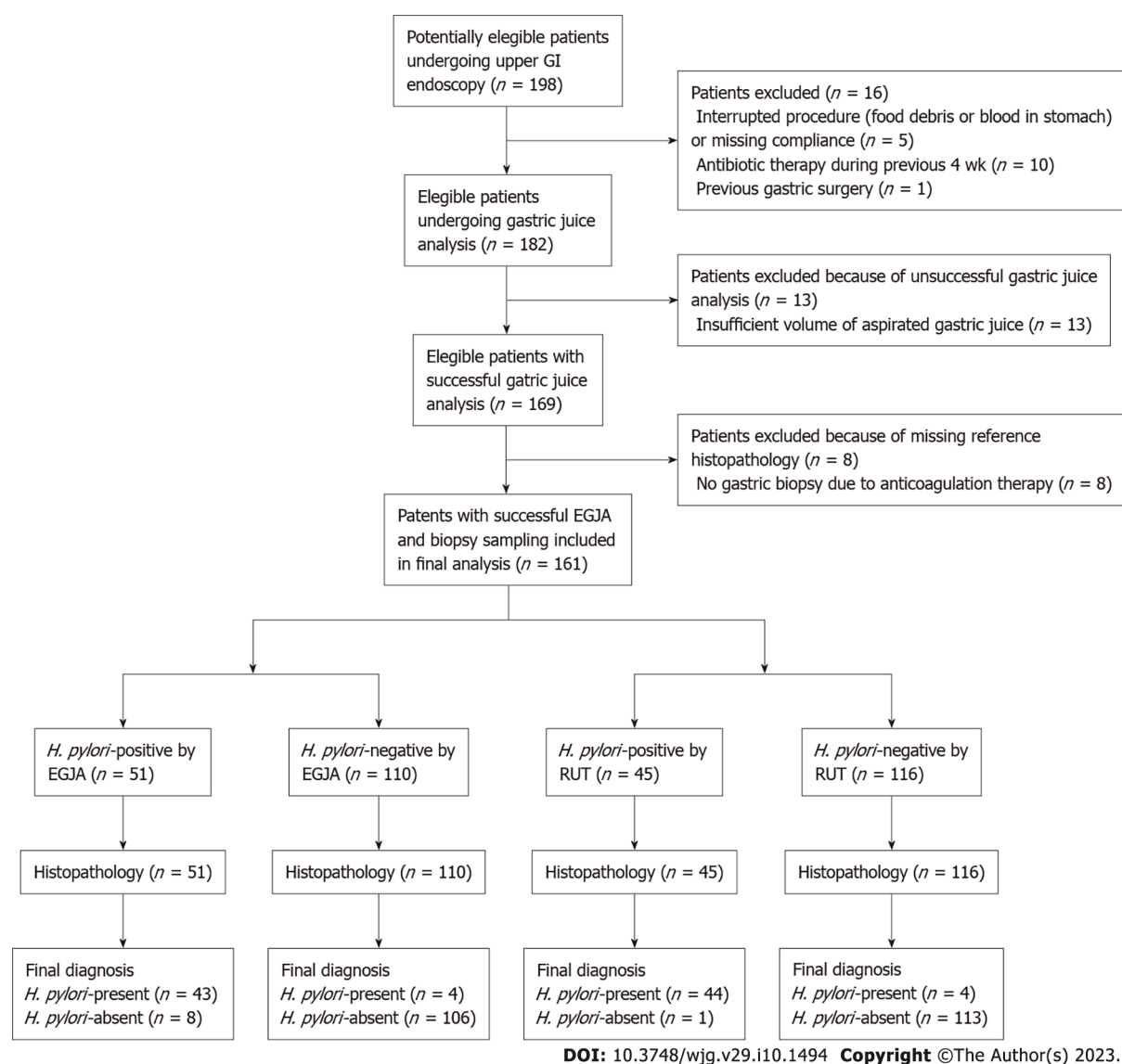


Figure 2 Flowchart according to Standards for Reporting Diagnostic Accuracy Studies guidelines of patient inclusion in the study and analysis. EGJA: Endofaster-based gastric juice analysis; *H. pylori*: *Helicobacter pylori*; RUT: Rapid urease test.

CONCLUSION

In conclusion, Endofaster's gastric juice analysis is a highly accurate method for the diagnosis of *H. pylori* infection, comparable to RUT. EGJA-based *H. pylori* diagnosis has an advantage in terms of on-site immediacy of diagnosis. In patients on PPI therapy, sensitivity is reduced, but NPV and specificity are not affected. Real-time detection of *H. pylori* along with the determination of gastric pH during endoscopy adds important information on the need for additional biopsies for more detailed histological assessment and antibiotic susceptibility testing.

ARTICLE HIGHLIGHTS

Research background

Diagnosis of *Helicobacter pylori* (*H. pylori*) infection can be rapidly achieved within the framework of gastroscopy by rapid urease test (RUT) or by gastric juice analysis with Endofaster.

Research motivation

The diagnostic performance of the Endofaster has not been compared with that of the RUT, which shares a similar characteristic in terms of providing results in a short-term temporal context through endoscopic examination.

Research objectives

The objective of this prospective study was to validate the diagnostic performance of the Endofaster for *H. pylori* detection in patients who underwent gastroscopy compared to the diagnostic accuracy of a standard RUT.

Research methods

Patients undergoing routine upper gastrointestinal endoscopy were prospectively recruited. Biopsies were taken to assess gastric histology according to the updated Sydney system and for RUT. Gastric juice sampling and analysis was performed using the Endofaster, and the diagnosis of *H. pylori* was based on real-time ammonium measurements. Histological detection of *H. pylori* served as the diagnostic gold standard for comparing Endofaster-based *H. pylori* diagnosis with RUT-based *H. pylori* detection.

Research results

Gastric juice analysis with Endofaster could reliably detect *H. pylori* with an overall sensitivity, specificity, accuracy, positive predictive value, and negative predictive value of 91.5%, 93.0%, 92.6%, 84.3%, and 96.4%, respectively. Gastric juice analysis with Endofaster and RUT were comparable in diagnostic performance and highly concordant in *H. pylori* detection (κ -value = 0.85).

Research conclusions

Endofaster's gastric juice analysis is a highly accurate method for the diagnosis of *H. pylori* infection, comparable to RUT. EGJA-based *H. pylori* diagnosis has an advantage in terms of on-site immediacy of diagnosis.

Research perspectives

Intraprocedural diagnosis of *H. pylori*-infection by Endofaster may guide additional sampling for antibiotic susceptibility testing in positive patients or avoid unnecessary biopsies in negative patients.

ACKNOWLEDGEMENTS

The authors would like to thank Ulrich Lang for organizing the data, Paul Muller, Tanja Nowak, Federico Urzi and the staff of NISO Biomed for technical assistance and for providing the Endofaster device free of charge during the recruitment period. Medical writing assistance was provided by Dr. Philip Benz.

FOOTNOTES

Author contributions: Vasapolli R, Schulz C, and Malfertheiner P designed the study, interpreted the data and drafted the manuscript; Vasapolli R, Suerbaum S, Schirra J, Mayerle J, Schulz C, and Malfertheiner P obtained funding and supervised the study procedures; Vasapolli R recruited suitable subjects, performed endoscopy, and collected samples; Vasapolli R, Macke L, Ailloud F, and Koch N registered data and performed statistical analyses; Neumann J performed the histological analysis; All authors read and approved the final version of the manuscript.

Supported by the Deutsches Zentrum für Infektionsforschung, Partner Site Munich, Germany, No. TTU 06.715_00; and the Bavarian Ministry of Science and the Arts within the framework of the Bavarian Research Network "New Strategies Against Multi-Resistant Pathogens by Means of Digital Networking – bayresq.net".

Institutional review board statement: This study was approved by the local ethics committee and government authorities and was conducted in accordance with current Good Clinical Practice guidelines and the Declaration of Helsinki. All recruited subjects provided written informed consent for participation.

Informed consent statement: Written informed consent was obtained from the participants.

Conflict-of-interest statement: The authors have nothing to disclose.

Data sharing statement: Data and analytic methods can be made available to other researchers upon request.

STROBE statement: The authors have read the STROBE statement, and the manuscript was prepared and revised according to the STROBE statement.

Open-Access: This article is an open-access article that was selected by an in-house editor and fully peer-reviewed by external reviewers. It is distributed in accordance with the Creative Commons Attribution NonCommercial (CC BY-NC 4.0) license, which permits others to distribute, remix, adapt, build upon this work non-commercially, and license

their derivative works on different terms, provided the original work is properly cited and the use is non-commercial. See: <https://creativecommons.org/licenses/by-nc/4.0/>

Country/Territory of origin: Germany

ORCID number: Riccardo Vasapolli 0000-0001-7150-5864; Florent Ailloud 0000-0001-9063-0839; Sebastian Suerbaum 0000-0001-9583-7505; Jens Neumann 0000-0001-9200-441X; Nadine Koch 0000-0002-3654-0733; Lukas Macke 0000-0002-7620-1744; Jörg Schirra 0000-0002-6887-2791; Julia Mayerle 0000-0002-3666-6459; Peter Malfertheiner 0000-0001-8439-9036; Christian Schulz 0000-0003-1841-1337.

Corresponding Author's Membership in Professional Societies: Deutsche Gesellschaft für Gastroenterologie, Verdauungs- und Stoffwechselkrankheiten; European Helicobacter and Microbiota Study Group; United European Gastroenterology.

S-Editor: Zhang H

L-Editor: A

P-Editor: Zhang H

REFERENCES

- 1 **Hooi JKY**, Lai WY, Ng WK, Suen MMY, Underwood FE, Tanyingoh D, Malfertheiner P, Graham DY, Wong VWS, Wu JCY, Chan FKL, Sung JJY, Kaplan GG, Ng SC. Global Prevalence of Helicobacter pylori Infection: Systematic Review and Meta-Analysis. *Gastroenterology* 2017; **153**: 420-429 [PMID: 28456631 DOI: 10.1053/j.gastro.2017.04.022]
- 2 **Sugano K**, Tack J, Kuipers EJ, Graham DY, El-Omar EM, Miura S, Haruma K, Asaka M, Uemura N, Malfertheiner P; faculty members of Kyoto Global Consensus Conference. Kyoto global consensus report on Helicobacter pylori gastritis. *Gut* 2015; **64**: 1353-1367 [PMID: 26187502 DOI: 10.1136/gutjnl-2015-309252]
- 3 **Malfertheiner P**, Megraud F, Rokkas T, Gisbert JP, Liou JM, Schulz C, Gasbarrini A, Hunt RH, Leja M, O'Morain C, Rugge M, Suerbaum S, Tilg H, Sugano K, El-Omar EM; European Helicobacter and Microbiota Study group. Management of Helicobacter pylori infection: the Maastricht VI/Florence consensus report. *Gut* 2022; Epub ahead of print [PMID: 35944925 DOI: 10.1136/gutjnl-2022-327745]
- 4 **Tucci A**, Tucci P, Bisceglia M, Marchegiani A, Papadopoli G, Fusaroli P, Spada A, Pistoletto MO, Cristino M, Poli L, Villani A, Bucci M, Marinelli M, Caletti G. Real-time detection of Helicobacter Pylori infection and atrophic gastritis: comparison between conventional methods and a novel device for gastric juice analysis during endoscopy. *Endoscopy* 2005; **37**: 966-976 [PMID: 16189769 DOI: 10.1055/s-2005-870373]
- 5 **Costamagna G**, Zullo A, Bizzotto A, Spada C, Hassan C, Riccioni ME, Marmo C, Strangio G, Di Rienzo TA, Cammarota G, Gasbarrini A, Repici A. Real-time diagnosis of H. pylori infection during endoscopy: Accuracy of an innovative tool (EndoFaster). *United European Gastroenterol J* 2016; **4**: 339-342 [PMID: 27403299 DOI: 10.1177/2050640615610021]
- 6 **World Medical Association**. World Medical Association Declaration of Helsinki: ethical principles for medical research involving human subjects. *JAMA* 2013; **310**: 2191-2194 [PMID: 24141714 DOI: 10.1001/jama.2013.281053]
- 7 **Dixon MF**, Genta RM, Yardley JH, Correa P. Classification and grading of gastritis. The updated Sydney System. International Workshop on the Histopathology of Gastritis, Houston 1994. *Am J Surg Pathol* 1996; **20**: 1161-1181 [PMID: 8827022 DOI: 10.1097/00000478-199610000-00001]
- 8 **Zullo A**, Germanà B, Galliani E, Iori A, de Pretis G, Manfredi G, Buscarini E, Buonocore MR, Monica F. Optimizing the searching for H. pylori in clinical practice with EndoFaster(□). *Dig Liver Dis* 2021; **53**: 772-775 [PMID: 33676857 DOI: 10.1016/j.dld.2021.02.004]
- 9 **Buderer NM**. Statistical methodology: I. Incorporating the prevalence of disease into the sample size calculation for sensitivity and specificity. *Acad Emerg Med* 1996; **3**: 895-900 [PMID: 8870764 DOI: 10.1111/j.1553-2712.1996.tb03538.x]
- 10 **Pohl D**, Keller PM, Bordier V, Wagner K. Review of current diagnostic methods and advances in Helicobacter pylori diagnostics in the era of next generation sequencing. *World J Gastroenterol* 2019; **25**: 4629-4660 [PMID: 31528091 DOI: 10.3748/wjg.v25.i32.4629]
- 11 **McNicholl AG**, Ducons J, Barrio J, Bujanda L, Forné-Bardera M, Aparcero R, Ponce J, Rivera R, Dedeu-Cuso JM, Garcia-Iglesias P, Montoro M, Bejerano A, Ber-Nieto Y, Madrigal B, Zapata E, Loras-Alastruey C, Castro M, Nevarez A, Mendez I, Bory-Ros F, Miquel-Planas M, Vera I, Nyssen OP, Gisbert JP; Helicobacter pylori Study Group of the Asociación Española de Gastroenterología (AEG). Accuracy of the Ultra-Rapid Urease Test for diagnosis of Helicobacter pylori infection. *Gastroenterol Hepatol* 2017; **40**: 651-657 [PMID: 28941945 DOI: 10.1016/j.gastrohep.2017.07.007]
- 12 **Said RM**, Cheah PL, Chin SC, Goh KL. Evaluation of a new biopsy urease test: Pronto Dry, for the diagnosis of Helicobacter pylori infection. *Eur J Gastroenterol Hepatol* 2004; **16**: 195-199 [PMID: 15075994 DOI: 10.1097/00042737-200402000-00012]
- 13 **Sánchez Rodríguez E**, Sánchez Aldehuelo R, Ríos León R, Martín Mateos RM, García García de Paredes A, Martín de Argila C, Caminoa A, Albillos A, Vázquez-Sequeiros E. Clinical validation of Endofaster® for a rapid diagnosis of Helicobacter pylori infection. *Rev Esp Enferm Dig* 2020; **112**: 23-26 [PMID: 31755285 DOI: 10.17235/reed.2019.6441/2019]
- 14 **Gatta L**, Vakil N, Ricci C, Osborn JF, Tampieri A, Perna F, Miglioli M, Vaira D. Effect of proton pump inhibitors and antacid therapy on 13C urea breath tests and stool test for Helicobacter pylori infection. *Am J Gastroenterol* 2004; **99**: 823-829 [PMID: 15128344 DOI: 10.1111/j.1572-0241.2004.30162.x]
- 15 **Lan HC**, Chen TS, Li AF, Chang FY, Lin HC. Additional corpus biopsy enhances the detection of Helicobacter pylori

- infection in a background of gastritis with atrophy. *BMC Gastroenterol* 2012; **12**: 182 [PMID: [23272897](#) DOI: [10.1186/1471-230X-12-182](#)]
- 16 **Logan RP**, Walker MM, Misiewicz JJ, Gummett PA, Karim QN, Baron JH. Changes in the intragastric distribution of *Helicobacter pylori* during treatment with omeprazole. *Gut* 1995; **36**: 12-16 [PMID: [7890214](#) DOI: [10.1136/gut.36.1.12](#)]
- 17 **Sanduleanu S**, Jonkers D, De Bruine A, Hameeteman W, Stockbrügger RW. Non-*Helicobacter pylori* bacterial flora during acid-suppressive therapy: differential findings in gastric juice and gastric mucosa. *Aliment Pharmacol Ther* 2001; **15**: 379-388 [PMID: [11207513](#) DOI: [10.1046/j.1365-2036.2001.00888.x](#)]
- 18 **Brandi G**, Biavati B, Calabrese C, Granata M, Nannetti A, Mattarelli P, Di Febo G, Saccoccio G, Biasco G. Urease-positive bacteria other than *Helicobacter pylori* in human gastric juice and mucosa. *Am J Gastroenterol* 2006; **101**: 1756-1761 [PMID: [16780553](#) DOI: [10.1111/j.1572-0241.2006.00698.x](#)]
- 19 **Genta RM**, Graham DY. Comparison of biopsy sites for the histopathologic diagnosis of *Helicobacter pylori*: a topographic study of *H. pylori* density and distribution. *Gastrointest Endosc* 1994; **40**: 342-345 [PMID: [7794303](#) DOI: [10.1016/s0016-5107\(94\)70067-2](#)]
- 20 **Perna F**, Ricci C, Gatta L, Bernabucci V, Cavina M, Miglioli M, Vaira D. Diagnostic accuracy of a new rapid urease test (Pronto Dry), before and after treatment of *Helicobacter pylori* infection. *Minerva Gastroenterol Dietol* 2005; **51**: 247-254 [PMID: [16280966](#)]
- 21 **Megraud F**, Bruyndonckx R, Coenen S, Wittkop L, Huang TD, Hoebeke M, Bénéjat L, Lehours P, Goossens H, Glupczynski Y; European *Helicobacter pylori* Antimicrobial Susceptibility Testing Working Group. *Helicobacter pylori* resistance to antibiotics in Europe in 2018 and its relationship to antibiotic consumption in the community. *Gut* 2021; **70**: 1815-1822 [PMID: [33837118](#) DOI: [10.1136/gutjnl-2021-324032](#)]
- 22 **Si XB**, Bi DY, Lan Y, Zhang S, Huo LY. Gastric Juice-Based Genotypic Methods for Diagnosis of *Helicobacter pylori* Infection and Antibiotic Resistance Testing: A Systematic Review and Meta-analysis. *Turk J Gastroenterol* 2021; **32**: 53-65 [PMID: [33893766](#) DOI: [10.5152/tjg.2020.20025](#)]
- 23 **Rugge M**, Meggio A, Pennelli G, Piscioi F, Giacomelli L, De Pretis G, Graham DY. Gastritis staging in clinical practice: the OLGA staging system. *Gut* 2007; **56**: 631-636 [PMID: [17142647](#) DOI: [10.1136/gut.2006.106666](#)]
- 24 **Capelle LG**, de Vries AC, Haringsma J, Ter Borg F, de Vries RA, Bruno MJ, van Dekken H, Meijer J, van Grieken NC, Kuipers EJ. The staging of gastritis with the OLGA system by using intestinal metaplasia as an accurate alternative for atrophic gastritis. *Gastrointest Endosc* 2010; **71**: 1150-1158 [PMID: [20381801](#) DOI: [10.1016/j.gie.2009.12.029](#)]